



Practice Cardiac Troponin I Kit Expressions and Concentrations of Cardiac Troponin I in Beef Cattle with Foot and Mouth Disease*

Halim Akın¹, Vehbi Güneş², İlnur Karaca Bekdik²

¹ Municipality of Elbistan, Kahramanmaraş- TURKEY

² Erciyes University, Faculty of Veterinary Medicine, Department of Internal Medicine, 38039, Kayseri-TURKEY

Summary: The aim of this study was to determine the expression of cTn-I with immunochromatographic strip kits, the concentrations of serum cTn-I in myocardial degeneration due to foot and mouth disease (FMD) with these parameters in beef cattle. For this purpose sixty-nine cattle with acute FMD (Group I), mean age 12.4±0.5 months old and 20 clinically healthy cattle (Group II), mean age 10.4±0.6 months old were used. Creatine kinase-MB (CK-MB), lactate dehydrogenase (LDH) activities, cTn-I concentrations and expression of cTn-I were determined in both groups. Mean CK-MB, LDH activities and cTn-I concentration were found as 795.1±70.8 U/L, 1305.9±51.4 U/L and 3.6±0.3 ng/ml respectively in cattle with FMD. The mean of the same parameters were 306±20.5 U/L, 1084.7±43.2 U/L and 1.1±0.02 ng/ml in Group II, respectively. These parameters in Group I were statistically higher than those of control group (p<0.05). The sensitivity and specificity of cTn-I kits for the diagnosis myocardial degeneration were 100% and 76.9%, respectively. Cardiac Tn-I tests were positive in the only five cattle with FMD, but these tests were negative in blood samples collected from healthy cattle. Macroscopic findings, serum cTn-I concentrations and positive cTn-I results were correlated with FMD cases suffering from myocardial degeneration. In conclusion, both quantitative cTn-I analyses and qualitative cTn-I expressions may be sensitive and specific marker for the determination of mortality rate in cattle with FMD, and can be used to predict the future cardiac disorders in cattle.

Key Words: Cattle, CK-MB, cTn-I, FMD, LDH

Şap Hastalıklı Besi Sığırlarında Pratik Kardiyak Troponin I Kit Sonuçları ve Kardiyak Troponin I Düzeyleri

Özet: Bu çalışmanın amacı, immünokromatografik test kiti ile şap hastalığı (FMD) bulunan besi sığırlarında cTn-I'nin belirlenmesi ve miyokard dejenerasyonlarında söz konusu parametrenin düzeylerini belirlemektir. Bu amaçla akut FMD'li (I. Grup) ortalama 12.4±0.5 aylık yaşta 69 adet ve klinik olarak sağlıklı (II. Grup) ortalama 10.4±0.6 aylık yaşta 20 adet sığır kullanıldı. Her iki grupta da kreatin kinaz-MB (CK-MB) ve laktat dehidrogenaz (LDH) aktiviteleri, cTn-I düzeyleri ve cTn-I varlığı belirlendi. FMD'li sığırlarda ortalama CK-MB ve LDH aktiviteleri, cTn-I düzeyi sırasıyla ortalama 795.1±70.8 U/L, 1305.9±51.4 U/L ve 3.6±0.3 ng/ml olarak bulundu. Aynı parametreler II. Grupta sırasıyla ortalama 306±20.5 U/L, 1084.7±43.2 U/L ve 1.1±0.02 ng/ml olduğu belirlendi. Bu parametreler I. Grupta, kontrol grubuna göre istatistiksel olarak yüksek bulundu (p<0.05). Pratik cTn-I kiti ile kalp kası dejenerasyonunun tanısında duyarlılık ve seçicilik oranları sırasıyla %100 ve %76.92 olarak bulundu. FMD'li sığırlardan yalnızca beşinde kardiyak Tn-I testleri pozitif sonuç verdi. Ancak bu pratik testler sağlıklı sığırlardan toplanan kan örneklerinde negatif idi. Makroskobik bulgular, serum cTn-I düzeyleri ve pozitif cTn-I sonuçları Şap hastalığına bağlı miyokard dejenerasyonu olan vakalarla uyumlu bulundu. Sonuç olarak, hem kantitatif cTn-I analizleri hem de kalitatif cTn-I varlığı FMD'li sığırlarda ölüm oranının belirlenmesi için duyarlı ve spesifik bir belirleyici olabileceği ve sığırlarda gelişebilecek kalp kası hastalıklarını belirlemek için kullanılabilirliği gösterilmiştir.

Anahtar Kelimeler: CK-MB, cTn-I, LDH, sığır, şap hastalığı.

Introduction

The clinical diagnosis of myocarditis in cattle is difficult and it is usually characterised by sudden death. The myocardial degenerations (MD) in cattle can

be diagnosed with necropsy and histopathological analyses. Radiographic examinations are not widely available in routine farm animal practice for diagnosis of myocardial diseases. Although cardiac ultrasound examination can be performed easily in field conditions, the usefulness of echocardiographic examinations is limited to the diagnosis of MD (7,20). Although making an accurate clinical diagnosis of MD is difficult, an early diagnosis will likely lead to a more favorable outcome. The

Geliş Tarihi / Submission Date : 24.01.2014

Kabul Tarihi / Accepted Date : 06.01.2015

*This study was supported by Erciyes University, Unit of Scientific Research Project (Project number: TSY-09-670)

ability to diagnose MD in farm animals is important because these animals could then be immediately slaughtered before sudden death occurs. An economical, noninvasive test that can be used to detect myocardial cell damage in cattle is needed (30).

The last clinical trials have indicated that serum cardiac troponins (cTns) are the earliest appearing biochemical markers in acute coronary disease of humans and that cardiac troponin-T (cTn-T) and cardiac troponin-I (cTn-I) are valuable biochemical indicators of myocyte degeneration. CTns are released into the blood circulation as a result of acute myocardial degeneration and necrosis (1).

Some previous studies suggested that circulating cTn-I might be used for the diagnosis of cattle suffering from MD due to FMD (12,29), traumatic reticuloperitonitis (11), idiopathic pericarditis (14), bacterial endocarditis (7). Troponin is one of the major regulatory components of thin filament in the heart muscle. It is located at regular interval along the strands and is a protein complex consisting of three subunits (Troponin-I, Troponin-T, Troponin-C) (8).

As the sequence of amino acids in these proteins is highly conserved between species (23), reagents used in human medicine have been validated for use in the cow (11), calf (12,29) and lambs (28). It may therefore be possible to diagnose myocardial degeneration in domestic animals that has resulted from various causes. Troponins play a role in the contraction and relaxation of striated muscles. Diagnostic and prognostic importance of Troponins has been determined in human beings with myocardial infarction (MI). Since troponins are released during even micro injuries to the heart muscle, cTn-I and cTn-T have been determined to be a better cardiac marker than other markers such as CK-MB, AST, LDH and myoglobin in MI (1,3,17). Cardiac Tn-I has been an excellent candidate biomarker of cardiac injury in all mammal species. O'Brien et al. (23) have demonstrated that the reactivity of cTn-I is higher for myocardium than skeletal muscle, and there is a marked sequence homologies between human cTn-I and bovine heart.

Myocarditis in domestic animals may result in sudden death. In young calves, one of the reasons for sudden death is foot-and-mouth disease (FMD). FMD is a contagious disease of ruminants with high morbidity, although mortality rate is considerably lower in adult cattle, young calves may die (mortality rate in calves may be up to 50%) before showing

any observable lesions because of virus-induced damage to the developing cells of the myocardium (2,32).

FMD is a contagious infection caused by a member of the Picornaviridae family of genus Aphtovirus (2,20,35). The virus affects cloven-footed animals in all ages (7). The disease characterized by vesicular lesions, erosion and ulcers on the oral mucosa, coronary band and teeth (27). The virus causes a high fever for two or three days, followed by vesicles inside the mouth and on the feet that may rupture and cause lameness. In generally myocarditis occur in the period of viremia of the disease before than secondary lesions in the mouth. Animals die as a result of acute heart failure and asphyxia (12,29).

Circulating cTn has been used recently for the early diagnosis of myocardial ischaemia and necrosis in human medicine (4,10,15,25). A few studies have been made of the concentrations of cTn in human cases of acute viral and idiopathic pericarditis (5,13). Although high concentrations of cTn I concentration were determined in serum of calf with FMD, according the best our knowledge there is no study determined the accuracy of the practical cardiac cTn I (12,16,29). For this reason this preliminary study was designed to determine the diagnostic importance of practice cTn-I kits in cattle with FMD. The aim of this present study was to determine the accuracy of practice kits results with concentrations in serum of cardiac troponin I and the rate of MD in beef cattle with FMD.

Materials and Methods

Animal:

In sixtynine crossbred beef cattle mean age 12.4 ± 0.5 months old clinically diagnosed FMD during a disease outbreak between 2008 and 2009 (Group I) were compared with 20 clinically healthy same bred (Group II) mean age 10.4 ± 0.6 months old in Kahramanmaraş district-Turkey.

After than clinically diagnosis of the FMD, samples of mucosa in the mouth and saliva samples for the accurate diagnosis and the determination of virus-type were placed in to the tubes with steryl glycerin buffer. These samples were immediately send to The Institute of Foot and Mouth Disease (Ankara, Turkey) through the Directorate of Agriculture of Elbistan District and final diagnosis was achieved. Control animals were obtained from a slaughterhouse. Blood samples were collected

before slaughter and heart tissue was taken from dead animals in Group I. Control animals were not age matched, but all control animals were above 1 year of age, ranging from 12 months to 24 months. This study was approved by the Local Ethic Comity for Animal Research of Erciyes University (Date: 15.08.2008, Approved Number:08/46)

Sampling:

Each animal was examined physically and then 9 ml blood without anticoagulant for CK-MB, LDH and cTn-I analyses were taken from a jugular vein. The samples were stored for an hour at room temperature and centrifuged at 3000 rpm and 1400 g for 15 minutes, and the serum was separated and stored at -20°C until analysed. Creatine Kinase-MB (CK-MB) and lactate dehydrogenase (LDH) activities were determined in serum samples of animals in the Central Laboratory of Erciyes University with the appropriate commercial kits in the Olympus AU 2700 (New York, USA) autoanalyser.

Analysis of Qualitative and Quantitative cTn-I:

Troponin-I with cardiac origin in order to determine the presence in the blood serum was used the test kits being commercial practical, near patient-per-immunoassay Kit, Cardi Kit Practical cTn-I (cTn-I Cardiac Marker Testing in vitro Nano-Check AMI; Nano-Ditech Corp., USA). A commercially available ELISA kit (Calbiotech, USA) was used to determine the concentration of cTn-I according to

the manufacturer's instructions. The optical densities of the samples were compared with a standard curve prepared from standards containing 0 to 14 ng/ml of cTn-I derived from human hearts.

Statistical analyses:

The data were analysed using the SPSS statistical package version 16.0 (SPSS Inc. Chicago, IL). The cut-off values by the receiver operating characteristic (ROC) curve technique, sensitivity, and specificity were calculated for concentration of cTn-I. Depending on the type of the variables, independent sample Student *t* test was performed for significant differences between groups, if it did not apply to normal distribution, Mann Whitney-U was also employed. The minimum acceptable concentration of significance was set at $p < 0.05$.

Results

Clinical Examination:

In Group I, the mean body temperature, heart rate and breathing numbers, statistically significantly higher than those of healthy cattle. The numbers of rumen movements were considerably lower than in the healthy controls (Table 1).

Asia 1 serotype of FMD virus was determined in the the samples sent to The Institute of Foot and Mouth Disease.

Table 1. Age. body temperature. heart rate. respiratory rate and the number of rumen contractions in the FMD and control groups.

Parameters	Group I (n=69)	Group II (n=20)	Statistical
	Mean \pm SEM	Mean \pm SEM	Significant
Age (Months)	12.4 \pm 0.5	10.4 \pm 0.6	P>0.05
Body Temperature ($^{\circ}\text{C}$)	39.3 \pm 0.07	38.1 \pm 0.04	P<0.05
Heart Rate (beats/min)	94.5 \pm 1.3	60.3 \pm 1.2	P<0.01
Respiratory Rate breaths/min	35.3 \pm 0.8	24.8 \pm 0.9	P<0.05
Rumen Motility contractions / 5min	3.7 \pm 0.07	8.6 \pm 0.3	P<0.01

Biochemical parameters:

Mean CK-MB, LDH activities and cTn-I concentrations were found as 795.1±70.8 U/L 1305.9±51.4 U/L and 3.6±0.3 ng/ml respectively in cattle with FMD. Same parameters were mean 306±20.5 U/L, 1084.7±43.2 U/L and 1.1±0.02 ng/ml in Group II, respectively. These parameters in Group I were statistically higher than those of group II (p<0.05) (Table 2).

The mean concentration of cTn-I was significantly higher in Group 1. In this study, the sensitivity and specificity of cTn-I testing for the diagnosis of myocardial degeneration were 100% and 76.9%, respectively. The sensitivity and specificity values and the positive and negative predictive values of cTn-I concentrations are shown in Table 3. ROC curves for cardiac troponin cassette kit results are presented in Figure 1.

Table 2. Serum cTn-I concentration and CK-MB. LDH activities in clinically healthy and cattle with foot and mouth disease.

Parameters	Group I (n = 69)	Group II (n= 20)	Statistical Significant
	Mean±SEM	Mean±SEM	
CK-MB (U/L)	795.1±70.8	306±20.5	P<0.001
LDH (U/L)	1305.9±51.4	1084.7±43.2	P<0.01
cTroponin I (ng/ml)	3.6±0.3	1.1±0.02	P<0.001

Table 3. Cardiac Troponin I cassette kits results of Receiver Operating Characteristic (ROC) Curve Analysis

	Cut-off value (ng/ml)	Sensitivity (95% CI)	Specificity (95% CI)	Area under curve (%)
Cardiac Troponin I	>3.618	100.00 47.8-100.0	76.92 (46.2-95.0)	93

%95 CI: Confidence Interval

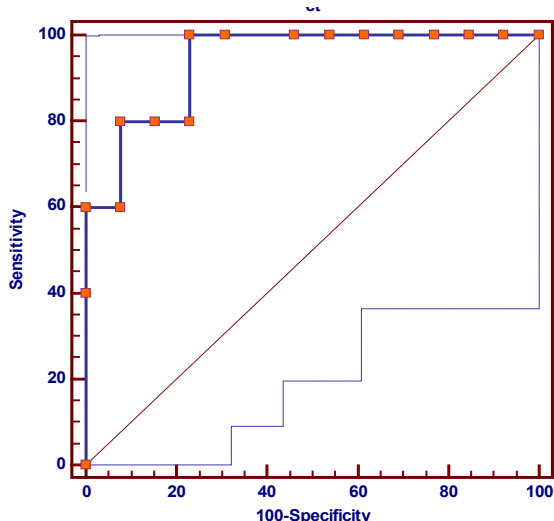


Figure 1. Receiver-operating characteristics (ROC) curves for cardiac troponin (ct) cassette kits in discriminating cattle with myocardial degeneration due to foot and mouth disease.

Cardiac Tn-I tests were determined as positive in the only five cattle with FMD (Figure 2), but these tests were negative in blood samples collected from healthy cattle (Figure 3). The data of cattle with the higher enzyme activity than the average value of the Group II. Although, the mean CK-MB values of the cardiac Tn-I positive cattle were numerically higher than those of cTn-I negative ones, it was not statistically significant. However, the

mean LDH, and cTn-I concentrations were statistically significant higher than the other groups (Table 1). Group I, cTn-I positive, despite the treatment applied to other animals, these animals were killed the next day. The various degrees myocardosis of heart muscle due to degeneration was observed in postmortem examination of these animals (Figure 4). Macroscopic findings, serum cTn-I concentrations and positive cTn-I results were correlated in FMD cases with myocardial degeneration.

The rate of all cattle which died or cTn-I positive cattle were 7.24% (5/69) in Group I. Rate of cTn-I positive was 20.8% (5/24) in cattle with high enzyme activities. Additionally mean LDH activity and cTn-I concentration were determined as 2072.4 ± 1186.1 U/L and 10.7 ± 5.4 ng/ml in cTn positive cases (n=5) respectively. These concentrations were statistically higher than the other animals (cTn negative cases and control animals) ($p < 0.05$).

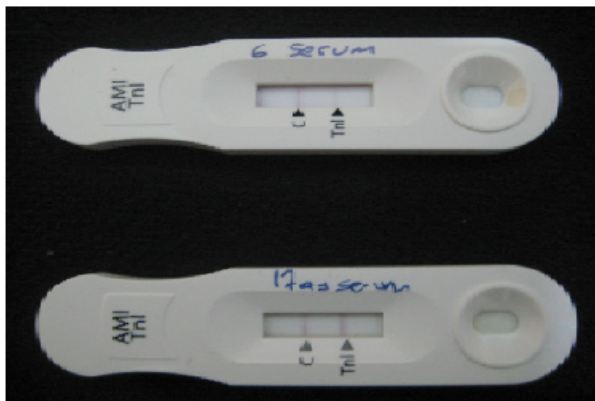


Figure 2. The result of cTn-I of two cattle that infected with foot and mouth disease. Double-line is positive result in reading window

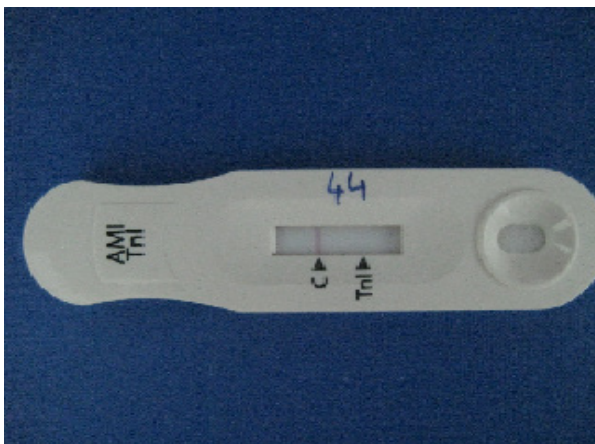


Figure 3. Indication of cTn-I of a healthy cattle. The only line in reading window is negative result.

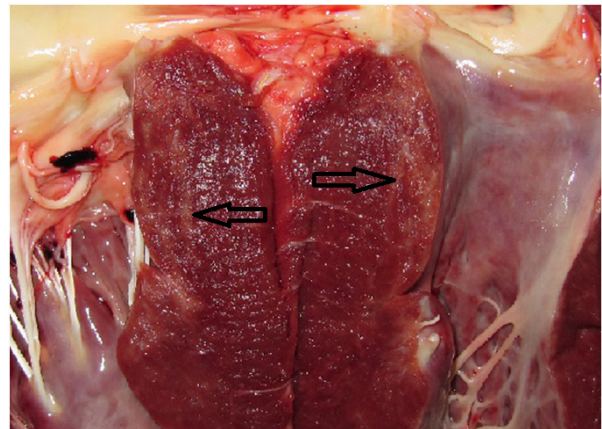


Figure 4. Myocardial degeneration in Interventricular septum (Arrows: the region that color change of heart muscle)

Discussion

Typical clinical symptoms reported in literature were observed in cattle suffer from foot and mouth disease in this study (2,20,22,27,35). Mean CK-MB and LDH activities obtained from the control group of this study were associated with findings of some previous studies reported for cattle (9,31). High mean enzyme activities indicated that heart muscle damage occurred in cattle, cTn-I result was compatible with the results of enzyme activity.

The mean cTn-I concentrations in cattle with FMD are in agreement with previous studies (6,18,19). Serum cTn-I concentrations for the 20 clinically healthy calves described herein were not consistent with values previously reported for healthy calves (34). Mean cTn I result in Group I of this study were lower than these concentration. In some studies have been shown that cTn-I results may vary by a factor of 100 fold from one assay and manufacturer to another. The causes of these differences may be the susceptibility to proteolytic degradation leading to appearance in serum of a wide diversity of peptides with different stabilities (30).

LDH activities may also be increased depending on the lung disease. Because abnormal breath sounds, tachypnea, and nasal mucopurulent discharge were seen in cattle, we confirmed to this opinion.

CK MB and LDH-1 can be increased when heart muscle is degenerated (26). Mean activities of these enzymes were determined as high in cattle with FMD. But CK-MB activities were large range

in Group I and standard deviation in this group was very high. The large range and high standard deviation are associated with short half-time of CK-MB according to cTn-I and LDH activities. For this reason, cTn-I was determined as an important diagnostic indicator for myocardial injury. Cardiac Tn-I practical test results were determined as positive in five animals and then these animals died and cardiac degeneration findings in necropsy were correlated with excessive elevation of cardiac enzymes indicating muscle damage. This findings is an indication that cTn-I is highly specific marker of heart muscle damage in cattle. In the present study concentrations of high cTn-I, positive cTn-I results in five cases were paralleled with the findings of previous studies (27,28). Positive results obtained from the practice kit associated with cTn-I concentrations released into the blood stream due to myocardial degeneration in cattle with foot and mouth disease. These results were consistent with the findings of high mean cTn-I concentration. Tunca et al. (28) reported that cTns were released into the blood circulation even at micro injuries of cardiac muscle. For this reason, cTns is a reliable marker than the other conventional test indicated the degeneration in heart muscle (1,17). Despite the decline in presence of cTn-I in the heart muscle of calves developed myocardial degeneration due to foot and mouth disease, high serum concentrations were determined in an another study (29).

The mean (\pm SD) cardiac troponin I concentrations in Practice cardiac kit positive cases (10.7 ± 2.3 ng/ml) were statistically significant ($p < 0.05$) higher than the FMD cases (Group I) (3.6 ± 0.3 ng/ml). These results were compatible with the death rate of both cases with high mean cTn-I concentration and practice kit positive cases. Additionally these result revealed that the prognostic significance of practice cTn-I kits in FMD cases.

The result of present study demonstrated that cattle diagnosed with FMD had significantly higher cTn-I concentrations in comparison with the healthy ones. This may substantiate incidence of myocyte damages in cattle because of Aftovirus. Mortality rate of FMD is usually less than 1% or 2% in old farm animals and above 20% in calves. Rate of cattle died or cTn-I positive cases were 7.24% for calf with 6-12 months age in this study. Because cTns have a high sensitivity and about absolute specificity and they released even in micro injuries into the blood stream (1,10,24), they can be used in the diagnosis and prognosis of viral myocarditis of farm animals. Because of the high correlation between

the high concentrations of troponins and clinical severity of the disease, life expectancy; not only for the separation of myocardial injury but also they can also be used for the determination of the risk (21). Sensitivity and specificity results of this study are harmonious with before study (24,33,34). In this study, some differences in sensitivity and specificity as compared with previous studies probably was owing to our limited and different number of patients. The serum concentrations of cTn-I correlate well with macroscopic changes in the myocardium.

Our results suggest that using a cutoff value of ≥ 3.618 ng/mL (Table 3). The diagnostic cTn cut-off value was higher in this study compared with a previous report (30). The possible explanations for this discrepancy may be due to the use of different commercially available immunoassays. In addition it may also due to large degenerative areas in the myocardium of dying animals.

cTn-I concentrations can be increased in cows with noncardiac disease as a result of adverse outcome in cows. This increased cTn-I concentrations may assist clinicians in evaluating of the treatment and prognosis (33).

Although the diagnosis of FMD can be done with clinical symptoms and necropsy of cattle in the field conditions, it is difficult to determine the myocardial degeneration in these animals. But this study showed that cTn practice kits produced for human have safely determined the heart muscle damage in cattle with foot and mouth disease. Cardiac Tn results obtained in this study were also increased the effectiveness of the physical examination and biochemical findings. The analysis of cTn-I in ruminants may be a sensitive and specific marker and they can be used for estimating myocardial degeneration in the veterinary field.

References

1. Azzazy HME, Christenson RH. Cardiac markers of acute coronary syndrome: Is there a case for point-of-care testing. *Clin Biochem* 2002; 35(1): 13-27.
2. Barnett PV, Cox SJ. The role of small ruminants in the epidemiology and transmission of foot-and-mouth disease. *Vet J* 1999; 158(1): 6-13.

3. Bertsch T, Bleuel H, Aufenanger J, Rebel W. Comparison of cardiac troponin-T and cardiac troponin-I concentrations in peripheral blood during orciprenaline induced tachycardia in rats. *Exp Toxicol Pathol* 1997; 49(6): 467-8.
4. Boccara G, Pouzeratte Y, Troncin R, Bonardet A, Boularan AM, Colson P, Mann C. The risk of cardiac injury during laparoscopic fundoplication. Cardiac troponin I and ECG study. *Acta Anaesthesiol Scand* 2000; 44(4): 398-402.
5. Brandt RR, Filzmaier K, Hanrath P. Circulating cardiac troponin I in acute pericarditis. *Am J Cardiol* 2001; 87(11): 1326-8.
6. Buczinski S, Bélanger AM. Bovine tricuspid endocarditis as a cause of increased serum concentration of cardiac troponins. *Can Vet J* 2010; 51(12): 195-7.
7. Buczinski S, Rezakhani A, Boerboom D. Heart disease in cattle: Diagnosis, therapeutic approaches and prognosis. *Vet J* 2010; 184(3): 258-63.
8. Cardinet GH. Skeletal muscle function. K. Kaneko, eds. In *Clinical Biochemistry of Domestic Animals*. Fifth Edition. San Diego: Academic Press, 1997a; pp. 410-4.
9. Cardinet GH. Skeletal muscle function. K. Kaneko, eds. In *Clinical Biochemistry of Domestic Animals*. Fifth Edition. San Diego: Academic Press, 1997b; pp. 424-9.
10. Christenson RH, Apple FS, Morgan DL, Alonsozola GL, Mascotti K, Olson M, McCormack RT, Wians FH Jr, Keffer JH, Duh SH. Cardiac troponin-I measurement with the access immunoassay system: analytical and clinical performance characteristics. *Clin Chem* 1998; 44(1): 52-60.
11. Gunes V, Atalan G, Citil M, Erdogan HM. Use of cardiac troponin kits for the qualitative determination of myocardial cell damage due to traumatic reticuloperitonitis in cattle. *Vet Rec* 2008; 162(16): 514-7.
12. Gunes V, Erdogan HM, Citil M, Ozcan K. Assay of cardiac troponins in the diagnosis of myocardial degeneration due to foot-and-mouth disease in a calf. *Vet Rec* 2005; 156(22): 714-5.
13. Imazio M, Demichelis B, Cecchi E, Belli R, Ghisio A, Bobbio M, Trincherro R. Cardiac troponin I in acute pericarditis. *J Am Coll Cardiol* 2003; 42(12): 2144-8.
14. Jesty SA, Sweeney RA, Dolente BA, Reef BA. Idiopathic and cardiac tamponade in two cows. *J Am Vet Med Assoc* 2005; 226(9): 1555-8.
15. Jurlander B, Clemensen P, Wagner GS, Grande P. Very early diagnosis and risk stratification of patients admitted with suspected acute myocardial infarction by the combined evaluation of a single serum value of cardiac troponin-T, myoglobin, and creatine kinase MB. *Eur Heart J* 2000; 21(5): 382-9.
16. Karapinar T, Dabak DO, Kuloğlu T, Bulut H. High cardiac troponin I plasma concentration in a calf with myocarditis. *Can Vet J* 2010; 51: 397-9.
17. M-Bardorff M, Hallermayer K, Schro A, Ebert C. Improved troponin T ELISA specific for cardiac troponin T isoform: assay development and analytical and clinical validation. *Clin Chem* 1999; 43(3): 458-66.
18. Mellanby RJ, Henry JP, Cash R, Ricketts SW, Bexiga R, Truyers I, Mellor DJ. Serum cardiac troponin I concentrations in cattle with cardiac and noncardiac disorders. *J Vet Intern Med* 2009; 23(4): 926-30.
19. Mellanby RJ, Henry JP, Cash R, Ricketts SW, Dias Bexiga JR, Mellor DJ. Serum cardiac troponin I concentrations in cattle with pericarditis. *Vet Rec* 2007; 161(13): 454-5.
20. Mezencio JMS, Babcock GD, Kramer E, Brown F. Evidence for the persistence of foot-and-mouth disease virus in pigs. *Vet J* 1999; 157(3): 213-7.

21. O'Brien PJ. Cardiac troponin is the most effective translational safety biomarker for myocardial injury in cardiotoxicity. *Toxicol* 2008; 245(3): 206-18.
22. O'Brien PJ, Dameron GW, Beck ML. Differential reactivity of cardiac and skeletal muscle from various species in two generations of cardiac troponin-T immunoassays. *Res Vet Sci* 1998; 65(2): 135-7.
23. O'Brien PJ, Landt Y, Ladenson JH. Differential reactivity of cardiac and skeletal muscle from various species in a cardiac troponin I immunoassay. *Clin Chem* 1997; 43(12): 2333-8.
24. Oyama MA, Sisson DD. Cardiac troponin-I concentration in dogs with cardiac disease. *J Vet Intern Med* 2004; 18(6): 831-9.
25. Panteghini M. Present issues in the determination of troponins and other markers of cardiac damage. *Clin Biochem* 2000; 33(3): 161-6.
26. Reef VB, Mcguirk SM. Diseases of the cardiovascular system. BP Smith. Eds. In *Large Animal Internal Medicine*. Third Edition. St. Louis: Mosby, 2002; pp. 443-78.
27. Smith BP. *Large Animal Internal Medicine*. Third Edition. Philadelphia/USA: Mosby-year book, 2002; p. 718.
28. Tunca R, Erdogan HM, Sonmez M, Citil M, Devrim AK, Erginsoy S, Uzlu E. Evaluation of cardiac troponin I and inducible nitric oxide synthase expressions in lambs with white muscle disease. *Turk J Vet Anim Sci* 2009; 33(1): 53-9.
29. Tunca R, Sozmen M, Erdogan HM, Citil M, Uzlu E, Ozen H, Gokce E. Determination of cardiac troponin I in the blood and heart of calves with foot-and-mouth disease. *J Vet Diagn Invest* 2008; 20(5): 598-605.
30. Undhad VV, Fefar DT, Jivani BM, Gupta H, Ghodasara DJ, Joshi BP, Prajapati KS. Cardiac troponin: An emerging cardiac biomarker in animal health. *Vet World* 2012; 5(8): 508-11.
31. Utlü N, Yücel O, Kaya N. Farklı ırk sığırlarda bazı serum enzim aktiviteleri. *Kafkas Univ Vet Fak Derg* 2005; 11(1): 39-41.
32. Van Vleet JF, Ferrans JV. Myocardial Disease of Animals. *Am J Pathol* 1986; 124(1): 98-178.
33. Varga A, Angelos JA, Graham TW, Chigerwe M. Preliminary investigation of cardiac troponin I concentration in cows with common production diseases. *J Vet Intern Med* 2013; 27(6): 1613-21.
34. Varga A, Schober KE, Walker WL, Lakritz J, Michael RD. Validation of a commercially available immunoassay for the measurement of bovine cardiac troponin I. *J Vet Intern Med* 2009; 23(2): 359-65.
35. Yang PC, Chu RM, Chung WB, Sung HT. Epidemiological characteristic and financial costs of the 1997 foot and-mouth disease epidemic in Taiwan. *Vet Rec* 1999; 145(25): 731-4.

Yazışma Adresi:

Prof. Dr. Vehbi GÜNEŞ
Erciyes Üniversitesi Veteriner Fakültesi,
İç Hastalıkları Anabilim Dalı,
Kayseri / TÜRKİYE
E-posta: vgunes@erciyes.edu.tr